

## IMPACT OF MUCORMYCOSIS IN NASAL CAVITY – OUR EXPERIENCE IN TERTIARY CARE CENTRE

B. Ganesh Kumar<sup>1</sup>, C. Karuppasamy<sup>1</sup>, K. Ramesh Babu<sup>2</sup>, D. Prince Peter Dhas<sup>3</sup>

Received : 09/12/2022  
Received in revised form : 01/01/2023  
Accepted : 15/01/2023

**Keywords:**

*Mucormycosis, Middle Turbinate, Inferior Turbinate, Septum, Floor of Nasal Cavity, Anterior and Posterior Ethmoid Arteries.*

**Corresponding Author:**

**Dr. D. Prince Peter Dhas,**  
Email: drprincembbs@gmail.com

DOI: 10.47009/jamp.2023.5.4.36

Source of Support: Nil,  
Conflict of Interest: None declared

*Int J Acad Med Pharm*  
2023; 5 (4); 170-173



<sup>1</sup>Associate Professor, Department of ENT, Thanjavur Medical College, Thanjavur, India.

<sup>2</sup>Associate Professor, Department of ENT, Govt. Thiruvavur Medical College, Thiruvavur, India.

<sup>3</sup>Assistant Professor, Department of ENT, Thanjavur Medical College, Thanjavur, India.

### Abstract

**Background:** Amongst all fungal infections Mucormycosis is very Fatal one. Commonly this starts from the Nose and later on extend to Paranasal Sinuses. In Lateral nasal wall Middle Turbinate involved in almost majority of cases. Arterial invasion is very common resulting in Thrombosis of blood vessels. This leads to Necrosis of the Turbinates and mucosa covering the nasal cavity. We can easily identify this Block colored lesion, which is called Eschar. So that only it is called as Black Fungus. To Study about the Impact of Mucormycosis in Nasal cavity like Various Turbinates. Septum and its Lining Mucosa. Study Design is Analytical Study, Retrospective Study. **Materials and Methods:** Study was conducted in our Dept of ENT, Govt Thanjavur Medical College, Tamil Nadu, India. Period of study is from April 2021 to July 2021. Total number of patients taken for study was 97. Patients with Extension into adjacent regions like Infra temporal fossa, Pterygopalatine fossae involvement. Intracranial involvement and Orbital involvement are Excluded. All patients are Underwent Endoscopic Debridement and Tissues sent for confirmation by Histology. Post operative Endocleaning and Systemic Amphotericin, Hypertonic Saline Irrigation and Regular follow up for 6 to 8 weeks. **Result:** In our study Males (65) are more affected than Females (32). 21 to 40 Years Age groups involved in 55 patients. Post Covid-19 (68) patients. Diabetes Mellitus association present in 75 cases. Middle Turbinate involvement in 43 patients followed by Inferior Turbinate (35) and Septum (19) cases. Lateral Nasal wall Anatomical variations presented was High Septal Deviation (60) and Osteo Meatal Crowding (37) cases. This Fungal infection was mostly Opportunistic infection. Strongly correlated with Immunodeficient conditions like Individuals with Poor Glycemic Control, On Prolonged steroid Therapy, Post Covid Status, Post Renal Transplant and Chronic Dialysis individuals. Vascular invasion is the hallmark of Mucor. Eschar tissue is seen depending upon the specific Artery involved like Anterior half of Middle Turbinate alone involved or sometime whole turbinate involved. Most of the cases High septal Deviation having some effects on Middle meatus and the OMC component and later results in Sinusitis. Earlier suspicious and Effective Debridement and Supportive Systemic Amphotericin and regular Postoperative follow up plays vital role in the management protocol regarding reduction of recurrences also. **Conclusion:** Males are affected more in our study. Commonly affected age group is 21 to 40 yrs. Middle Turbinate followed by Nasal Septum and Inferior Turbinate are the seen. Septal Deviation at the level of Middle Turbinate level hampers the Ventilation of Middle Meatus and predisposing to development of Sinusitis. Immuno compromised status is main factor. Proper Septal Correction alone plays a vital role in preventing development of Mucor. Treating the Immunodeficient conditions and Early Surgical debridement and Systemic Amphotericin is Very effective. Regular Follow up with Hypertonic Saline wash reduces recurrences.

## INTRODUCTION

Mucormycosis was described by Paultaffin. Class of Zygomycetes and Order of Mucorales. Other Genera included in this family are Rhizopus, Rhizomucor, Absidia. Sinonasal mucor was commonly caused by Rhizopus. Rapid progression with high virulence was characteristic one. Wasted Foods and Soil are the main source of living.<sup>[1]</sup>

Angioinvasion occurs close the Internal layer of Elastic lamina of arteries and results thrombus formation and reducing the flow of blood finally results in Dead tissues. After invasion into arteries the chances of spread to adjacent vital regions like Orbit and Intracranium is common. Mostly presents as Acute forms only like Rhino-Orbital, Rhino-Cerebral, Pulmonary and Disseminated forms.<sup>[2]</sup>

Vulnerable groups are those who takes prolonged immunosuppressants, Uncontrolled High Sugar level patients, on Chronic Renal dialysis and transplanted patients. Prolonged use of Penicillin group of Antibiotics alter the bacterial flora and favors the growth of candida in alimentary system.<sup>[3]</sup>

Augmentin (Amoxicillin and Clavulanic acid) alters the gut flora by its bactericidal effects on Streptococci (Normal gut Flora) and augments the Fungal growth.<sup>[4]</sup>

In India the occurrence rate was 0.14% per 1000 population. But in Worldwide it was around 0.005 to 1.5% only. It was 75 times higher than the Developed countries. Death rate varies from 35 to 40% in immunologically sound groups and around 75 to 80 % in immune compromise patients.

Presenting Symptoms are Nasal Obstruction Unilateral or Bilateral, Mucopurulent foul smelling Nasal Discharge, Hypoaesthesia over the Malar region and Head ache if it invades the adjacent Orbit and Cranium.<sup>[5]</sup>

Biopsy can be taken during the First visit itself by using Endoscope, because there won't be No Pain and Bleeding During the procedure because of Necrosed tissues. By that we can start our treatment as early as possible and avoid unnecessary complications.<sup>[6]</sup>

PUO (Pyrexia of Unknown Origin) for beyond 2 days even after the proper Antibiotics and Adequate Doses cases associated with Prominent Nasal Symptoms, we have to think of Mucor if they are also immune compromised individuals.<sup>[7]</sup>

Swab from the Nasal mucosa with Fungal Stain of KOH with Colcours White Method is highly sensitive to detect Fungal Hyphae. Tissues are dissolved by KOH and Colcours white binds with fungal wall due to its Optic binding nature. It was demonstrated better by Florescent Microscope. Stains commonly used are PAS (Periodic Acid Schiff), GMS (Gomeric Methanamine Silver). GMS most Sensitive.<sup>[8]</sup>

Mucor Hyphae are large (5-50m) Nonseptate with Right angle Branching and Irregular. It will occlude the vessel leading to Obliterative endarteritis. In Contrast the Aspergillus having Small Hyphae (2.5 -

5m), 45 degree angled branching with Non Obliterative Vasculitis. Classification of Fungal sinusitis based on the Histology was given by Shazoetal.<sup>[9]</sup>

CT PNS plays major role to confirm the Extension of Disease, Bony erosion, to know the Periantral Fat plane involvement in early stage. To get better idea about soft tissue involvement and Intracranial involvement MRI is the choice. In T1 weighted image Iso to Hypo intense lesion and in T2 weighted images Variable intense but mostly Hypo intense lesion in Fungal sinus disease. It is because of Concentration of Manganese and Iron by the Mucor. Due the necrosis the Turbinates look Black (Eschar) and in MRI it was Completely Hypointense and called commonly the Black Turbinate Sign.<sup>[10]</sup>

### Objectives:

#### To Study about

1. Mucormycosis involvement in Turbinates, Septum and Floor of Nasal cavity,
2. The Effect of Septal Deviation in development of Sinusitis & Vulnerability for Mucormycosis development.

**Study Design:** Analytical Study, Retrospective Study.

## MATERIALS AND METHODS

Study was conducted in ENT Department Govt Thanjavur Medical College Thanjavur from April 2021 to July 2021. Total number of patients taken for study was 97.

Cases with Extension into adjacent regions like Infra temporal fossa, Pterygopalatine fossae and Intracranial involvement and Orbital involvement are Excluded.

Early Symptoms of Mucor are taken into account. All cases underwent DNE followed by CT PNS followed by MRI PNS.

All cases underwent Endoscopic Debridement and the removed material sent for HPE. Systemic Amphotericin was given to all cases depending upon the Renal Status. Proper Glycemic Control was important. After Discharge regular weekly Followup for

4-6 weeks with Salvage Therapy with T. Posaconazole is very effective in reduction of Recurrence.

## RESULTS

[Table 1 Figure 1] shows that Males (65) are more commonly involved than females (32).

[Table 2 and Figure 2] demonstrates the Age group distribution. In our study 21 to 40 years age group are more involved (55) followed by 41 to 60 years of age group which was around 25 in numbers. 0-20 years are least commonly involved.

[Table 3 and Figure 3] shows detail about the predisposing factors for this Mucor mycosis. Strong Positive association with Post Covid status, Diabetes and Prolonged Steroid therapy. But Negative

relationship with Oxygen Therapy which was the main treatment in Covid-19 Second wave.

[Table 4 and Figure 4] explains about the Turbino septal components involvement. In our study Middle turbinate is involved in huge numbers (43) followed by Nasal Septum(35) and the Inferior turbinate involved in 19 patients.

[Table 5 and Figure 5] shows the relationship between variation of anatomical factors and its correlation with sinusitis development. High septal deviation present in more number of cases (60) than the Crowding of Osteo meatal Complex (37).

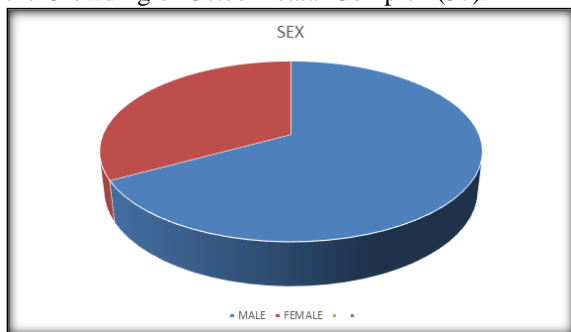


Figure 1: Sex

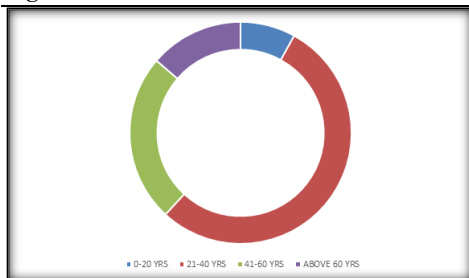


Figure 2: AGE GROUP

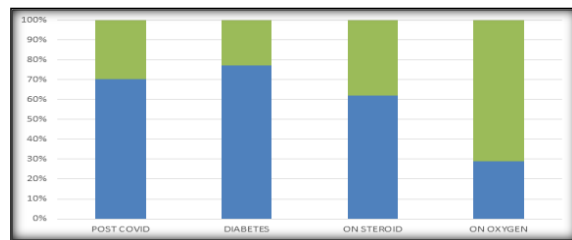


Figure 3: Predisposing Factors

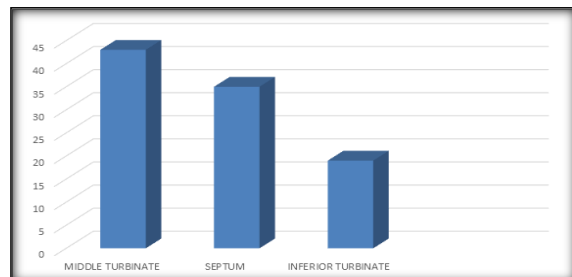


Figure 4: Components

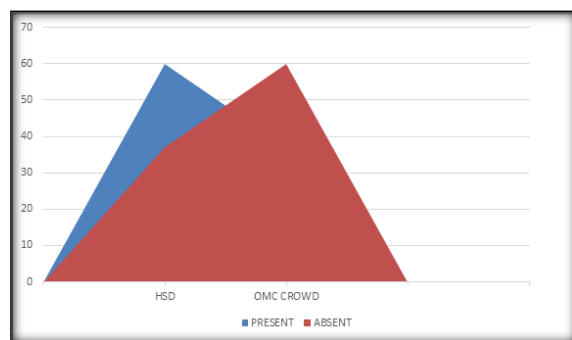


Figure 5: Anatomical Factors

Table 1: Gender Distribution

Sex	Number of patients
Male	65
Female	32

Table 2: Age Group Distribution

Age Groups	Numbers
0-20 years	03
21-40 years	55
41-60 years	25
Above 60 years	14

Table 3: Predisposing Factors

Predisposing Factors	Present	Absent
Post Covid	68	29
Diabetes	75	22
Steroid Therapy	60	37
Oxygen Therapy	28	69

Table 4: Turbino Septal Involvements

Components	Numbers
Middle turbinate	43
Nasal septum	35
Inferior turbinate	19

Table 5: Anatomical Factors in Nasal Cavity

Anatomical Factors	Present	Absent
Deviated Septum	60	37
OMC Crowding	37	60

## DISCUSSION

Normally the fungal infection of Nose and Paranasal sinus are very limited incidence only. Mostly related with Allergic aetiology only like Chronic Allergic Fungal Sinusitis. But it was abnormally High incidence during this Covid Pandemic only. Mucor commonly associated with Diabetic Keto acidosis. Acidic environment hampers the activity of Phagocytes and favors for Fungal infections.<sup>[11]</sup> Route of entry of this fungus through the Nose and Paranasal sinus. From here it extends posteriorly to Sphenoid Sinus and Cavernous Sinus, Inferiorly to Palate, Superiorly into Cranium, Laterally into Orbital cavity. Angioinvasion is main mode of spread, mostly through Arteries followed by veins.

This fungus enters into the vessel near Internal Elastic Lamina and detach this from the Media. This will end up with Severe damage of Vessel wall Endothelium followed by the formation of Thrombus leading to Ischemia of corresponding regions. Dead tissue provide positive environment for the growth of Fungus.<sup>[12]</sup>

In this study large number of cases associated with Anterior Ethmoid Artery involvement presenting with Necrosis of Anterior half of Middle Turbinate. Rest of the cases presents as Necrosis of Posterior of Middle Turbinate due to Posterior Ethmoidal Artery involvement.

Since the Ethmoidal Artery travels in Orbit and Cranial cavity, Complications are more common when this vessel is involved. During resection of Middle Turbinate, leaving the Axilla of MT is very important, because it acts as surface landmark for revision surgery.

Septal necrosis common in Posterior Bony part than the Anterior Cartilaginous part due to involvement of Posterior septal Branch of Sphenopalatine artery. Posterior Septectomy is treatment of choice for this condition.

Inferior Turbinate necrosis due to Posterior Lateral Nasal Branch of Sphenopalatine artery. Total removal of IT leads to exposure of Bones adjacent to removal site and prone for Osteomyelitis changes. Through curetting till fresh bleeding is mandatory.

Mucosa covering the Nasal cavity Floor leads to Osteomyelitis of Palate and further resulting in Oro Nasal Fistula.

High septal deviation is associated with development of Acute sinusitis and affecting its functions like Ventilation and Drainage. So Septal correction prevents the further development of dreadful complications like Mucor. So prior Septal Correction was a Positive Factor for less chance of developing fungal infections. During Mucormycosis debridement Septal correction is very important.

Osteo Meatal Complex was the Basic Unit of Sinus. It was bounded Medially by Middle Turbinate, Laterally Lamina Papyracea, Posteriorly Bulla Ethmoidalis and Anteriorly by Uncinate Process.

Variations of the OMC boundaries like Concho Bullosa, Paradoxical Middle Turbinate, Prominent Bulla leads to development of Sinusitis and later chance of Mucormycosis. So previously patients underwent for FESS and Septal corrections are having Less chance of developing this condition.

Adequate control of Predisposing Factors and Previous SMR and FESS done patients are less chances of developing Mucor. PostOperative systemic Amphotericin and Regular Endocleaning minimum once a week for 4-6 Weeks is mandatory. Salvage therapy with Oral Posaconazole also having vital role to reduce the recurrence.

## CONCLUSION

In our study Male patients are involved more in numbers. Commonly affects the Young age groups around 21 to 40 years. Most of the patients on treatment with Steroid and having uncontrolled status of blood glucose. High septal deviation present in almost 75% of cases than the OMC crowding. In this study we found Middle turbinate involved in more and followed by Nasal septum and Inferior turbinate. Regular Endoscopic examination of nose will reveal the diseased status and Early debridement with Adequate Amphotericin and Regular follow up with Endo cleaning and Oral antifungal treatment will certainly reduce the recurrence.

## REFERENCES

1. Ferguson BJ, Mucor mycosis of Nose and Paranasal sinuses. *Otolaryngol Clinics of North America* 2000; 33: 349-365.
2. Leitner C, Holfmann J, Zerfowski M, Reinert S. Mucor mycosis: Necrotising soft tissue lesions of face. *J Oral Maxillo Fac Surgery* 2003; 61: 1354-8.
3. Kinsman OS, Pitblado K. *Candida albicans* Gastrointestinal colonization and invasion in the mouse: Effect of Antibacterial dosing, Antifungal therapy, and Immunosuppression. *Mycoses* 1989; 32: 372-6.
4. Kerr Jr. Bacterial Inhibition of Fungal growth and Pathogenicity. *MicrobEcol Health Dis* 1999; 11: 129-42.
5. Idris N, Lim LH. Nasal Eschar: A Warning Sign of Potentially Fatal Invasive Fungal sinusitis in Immunocompromised Children. *J Ped Haemato Oncol*. 2012; 34(4): e134-6.
6. Gillespie MB, O'Malley BW. An Algorithmic approach to the diagnosis and management of Invasive fungal sinusitis in immunocompromised patient. *Otolaryngol Clin North America*. 2000; 33: (2): 323-334.
7. Park AH, Muntz HR, Smith ME et al. Pediatric Invasive Fungal Rhino Sinusitis in immunocompromised children with cancer. *Otolaryngol Head Neck Surgery* 2005; 133(3):411-6.
8. Schell WA. Fungal Stains and Histopathology of Fungal rhinosinusitis. *Otolaryngol Clin of North America*. 2000; 33(2): 251-76.
9. DeShazo RD, O'Brein M, Chapin K et al. a new classification and Diagnostic criteria for Fungal sinusitis. *Arch Otolaryngol Head Neck Surgery*. 1997; 123(11): 1181-8.
10. M.R.Terk, D.J.Underwood, C.S.Zee, P.M.Colletti, MR Imaging in Rhinocerebral and Intracerebral Mucor mycosis with CT and Pathologic Correlation. *MagnReson Imaging*, 10(1992), pp. 81-87.
11. Abramson E, Wilson D, Arky RA. Rhinocerebral Phycomycosis in association with Diabetic ketoacidosis. *Ann Int Med* .1967; 66: 735-42.
12. Petrikos G, Skiada A, Sambatakou H et al. Mucor mycosis: Ten years Experience in Tertiary care centre in Greece. *EurJou of Clin Microbiol Infect Dis* 2003; 22: 753-756.